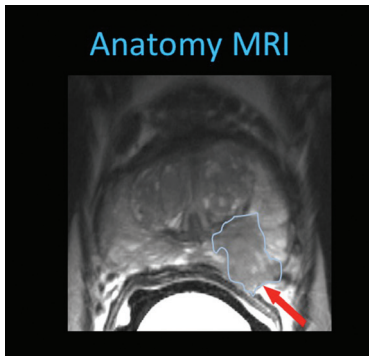
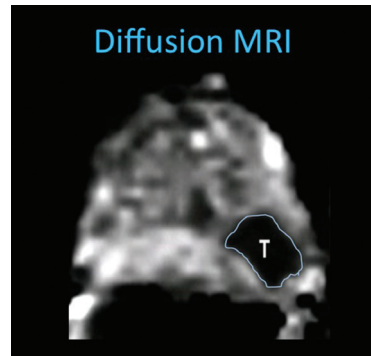




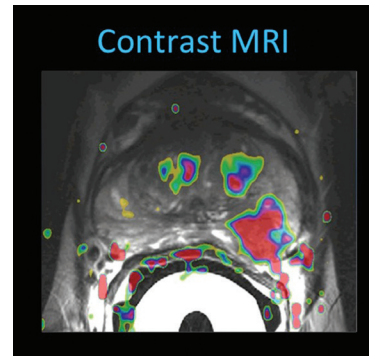
Scanned Alive



Anatomy MRI



Diffusion MRI



Contrast MRI

With the advent of multi-parametric Magnetic Resonance Imaging (mpMRI) the ability to find prostate cancer early is significantly increased. The likelihood is that with early diagnosis there is a greater chance that the man will not suffer from prostate cancer.

The “multi-Parameters” are as follows:

The multi parametric MRI scanner has the ability to define the anatomy of the prostate and therefore show the distortion of the normal tissues as shown in the first image (picture 1).

Diffusion Weighted Imaging or DWI is a method of measuring the movement of protons which are particles smaller than atoms as they move through water in the body. In cases of cancer there can be different patterns of movement which can be shown in picture 2. The cancer appears like a “black hole”.

It is particularly useful for picking up more aggressive cancers but may also show non-aggressive cancers which do not require aggressive treatment and can be followed up with serial MRI's instead.

Dynamic Contrast Enhancement (DCE) is a method of showing the properties associated with the transfer of fluid between the blood vessels and the tissues themselves. This is affected by the blood flow and the “leakiness” of the blood vessels. Cancer can have characteristic changes which are different from normal tissue and can be shown in a 3D colour image as shown in picture 3.

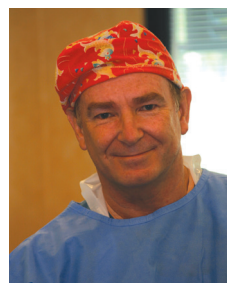Unfortunately, it is still necessary to take samples of the area to be sure that it is cancer and what type. Usually, only one or two biopsies of the detected lesion under MRI guidance are required. This is carried out with the aid of a robot device which enables us to accurately pinpoint the lesion concerned. In fact, in 90% of cases MRI detects the tumour at exactly the right location and around 50% of the tumours found are non-aggressive

and do not need treatment.

This process of imaging and diagnosis was developed by Prof. Jelle Barentsz at the Radboud University Medical Center in Nijmegen, The Netherlands and is now available in Cairns. In fact, there are only eight centers of excellence worldwide with the availability of this technology and expertise.

It is important to note that the Dutch Institute for Healthcare Improvement (CBO) guideline 1.3.3.1.1 states that modern MRI is the best option for the detection of prostate cancer in the case of an increased PSA and a previous negative TRUS biopsy. Also, 1.3.3.1.2 of the CBO guideline states that an MRI must be done prior to treatment for prostate cancer. In addition, the MRI is able to detect signs that the disease may have spread to other areas using special contrast studies for that.

It will be possible to carry out localised prostate cancer treatment using focal Cryotherapy to small lesions within the prostate without the need for major surgery. I hope that this will put MRI screening as the standard of care in Australia so that management can be more tailored to the individual in the future.



DR NEIL GORDON

*Urologist
Urological Surgeon at Cairns Urology
M.B.B.S (Melb)
F.R.C.S (Glasg) F.R.C.S Ed
F.R.A.C.S., F.I.C.S*



Prostate MR Center of Excellence

multi parametric Magnetic Resonance Imaging (mpMRI)

- Gives an overall picture with highly defined 3D colour images
- Particularly useful for those men with an elevated Prostate Specific Antigen (PSA) blood test
- Only one or two biopsies are usually required

98 Spence Street
Cairns, QLD 4870, Australia

PO Box 7787
Cairns, QLD 4870, Australia

P (07) 4041 0700
F (07) 4041 4007

reception@cairns-urology.com.au
www.cryotherapy.com.au

Cairns-Urology.com.au

facebook.com/Cairns.Urology

twitter.com/CairnsUrology

